

COVID-19 progression, frailty, and use of prolonged continuous positive airway pressure as a ward-based treatment: Lessons to be learnt from a case

Dominic L Sykes, Ahalya Parthasarthy, Oliver I Brown, Michael G Crooks, Shoaib Faruqi

Respiratory Research Group, Hull University Teaching Hospitals, HU16 5JQ, UK

ABSTRACT

Coronavirus disease 19 (COVID-19) poses the greatest public health threat in 100 years, with cases rising rapidly in many countries around the world. We report a case of a 78-year-old female who exhibited a biphasic course of COVID-19; showing initial clinical improvement followed by deterioration before making a full recovery. The patient was managed with prolonged continuous positive airway pressure (CPAP) and supportive care. In total, 24 days of treatment with CPAP was administered. We emphasize the role of CPAP in the management of severely hypoxemic patients who are inappropriate for mechanical ventilation and describe the role of adequate nutrition and hydration for such patients.

KEY WORDS: Acute respiratory distress syndrome, continuous positive airway pressure, COVID-19

Address for correspondence: Dr. Dominic L Sykes, Daisy Building, Castle Hill Hospital, HU16 5JQ, UK. E-mail: dominicsykes5@gmail.com

Submitted: 13-Jul-2020

Accepted: 18-Jul-2020

Published: 16-Sep-2020

INTRODUCTION

Coronavirus disease 19 (COVID-19) has evolved into an international public health crisis. As of June 30, 2020, there were over 10.5 million reported cases and >510,000 deaths worldwide. Several countries, including the United Kingdom (UK), are now past the first peak of the crisis and it is vital that lessons can be learned for future surges and for nations approaching their first peak. India is currently among the 5 most-affected countries internationally and cases are continuing to rise; >20,000 new cases are being reported daily and total numbers are approaching a million.^[1,2]

Although most people with COVID-19 have a mild disease, others require hospitalization and a small but important minority will develop organ failure.^[3] A small proportion of

patients experience a “biphasic” course in their condition, characterized by initial improvement before deterioration. It has been suggested that this may result from an aberrant inflammatory response or “cytokine storm” in the later phase of the illness.^[4]

Continuous positive airway pressure (CPAP) is a noninvasive form of positive airway pressure ventilation. It delivers a constant pressure throughout the respiratory cycle, preventing small airway collapse and allowing patient-initiated breaths to recruit more lung capacity.^[5] CPAP was initially used in COVID-19 with circumspection due to poor evidence in the management of acute respiratory distress syndrome (ARDS) and pneumonia.^[6] However,

This is an open access journal, and articles are distributed under the terms of the Creative Commons Attribution-NonCommercial-ShareAlike 4.0 License, which allows others to remix, tweak, and build upon the work non-commercially, as long as appropriate credit is given and the new creations are licensed under the identical terms.

For reprints contact: WKHLRPMedknow_reprints@wolterskluwer.com

How to cite this article: Sykes DL, Parthasarthy A, Brown OI, Crooks MG, Faruqi S. COVID-19 progression, frailty, and use of prolonged continuous positive airway pressure as a ward-based treatment: Lessons to be learnt from a case. Lung India 2021;38:S64-8.

Access this article online	
Quick Response Code: 	Website: www.lungindia.com
	DOI: 10.4103/lungindia.lungindia_583_20

awaiting robust published evidence, it is increasingly acknowledged as having an important role in the management of hypoxemic respiratory failure caused by COVID-19.^[7,8]

We report a case not deemed fit for invasive mechanical ventilation, successfully managed on a respiratory ward with prolonged use of CPAP. Our case also conveys the “biphasic” nature of the disease as well as how biochemical markers may reflect this. We also emphasize the role of adequate nutrition and hydration.

CASE REPORT

A 78-year-old female ex-smoker was admitted with an 8-day history of nonproductive cough, fever, and worsening malaise. Prior to admission, she required help with high-order activities of daily living, such as heavy housework; she was relatively independent with activities of daily living, receiving some support from her family for the same, but she rarely left her house. This put her in the category of “mildly frail” on the Clinical Frailty Scale 5.^[9] Her past medical history included hypertension, chronic obstructive pulmonary disease (COPD), and diet-controlled diabetes mellitus-type 2. Her vital signs following initial assessment were: Heart rate 94/min, blood pressure 104/71 mmHg, respiratory rate 19/min, temperature 36.2° C and oxygen saturation 92% on 6 L O₂ delivered through nasal cannula. Her laboratory results revealed: White cell count $3.4 \times 10^9/L$ (normal range: $4.0\text{--}11.0 \times 10^9/L$), neutrophils $2.43 \times 10^9/L$ (2.0–7.7), lymphocyte $0.82 \times 10^9/L$ (0.8–3.4), C-reactive protein (CRP) 100 mg/L (0–8), urea 4.7 mmol/L (3.0–7.6), and creatinine of 62 $\mu\text{mol/L}$ (65–114). Chest X-ray (CXR) showed bilateral infiltrates that were most apparent in the left middle and right lower zones [Figure 1a].

She was initially managed as suspected COVID-19 pneumonia with an exacerbation of COPD. On day-3 of admission she deteriorated significantly; she became cyanosed and tachypnoeic at 30 breaths per minute and 15 L/min oxygen via a mask with a reservoir bag was required to achieve oxygen saturation of 90%. Molecular testing confirmed the presence of severe acute respiratory syndrome coronavirus 2 on nasopharyngeal swab, confirming the diagnosis of COVID-19 pneumonia. Arterial blood gas analysis on 15 L/min oxygen via a mask with a reservoir bag showed: pH 7.49, pCO₂–4.9 kPa, and pO₂–4.2 kPa, in keeping with severe lung injury. She was commenced on CPAP of 10 cm H₂O with 60% fraction of inspired oxygen (FiO₂). Following initiation of CPAP, she improved symptomatically with reduction in respiratory rate and achieved saturations at 92% on 60% FiO₂. The CPAP management strategy was to titrate pressures up to a maximum of 15 cm H₂O with an aim to keep FiO₂ requirements to 60% or less, as far as possible, with target saturation of 88%–92%.^[10] A do-not-attempt resuscitation order was placed and agreed with the family, which

included the decision that the patient would not be suitable for invasive ventilation through an endotracheal tube; this was based on the patient’s pre-morbid functional status and perceived poor prognosis with these interventions.

On day 4 of the admission, her oxygen requirements increased to an FiO₂ of 90%, and she was CPAP dependent on 15 cm H₂O, rapidly desaturating when it was removed. A nasogastric (NG) tube was inserted to maintain both nutrition and hydration. A repeat CXR showed worsening consolidation in both lungs consistent with worsening COVID-19 pneumonia [Figure 1b]. Rising inflammatory markers prompted the initiation of empirical antibiotics (Moxifloxacin) to cover possible secondary bacterial infection [Figure 2]. The patient’s condition initially stabilized; by day 10, she was weaned to overnight CPAP only, maintaining adequate oxygen saturation on 2 L/min of oxygen delivered through nasal cannula and the feeding NG-tube was removed.

Despite initial improvement, she experienced a second phase of clinical deterioration on day 12 (20 days from onset of symptoms) with worsening respiratory parameters (respiratory rate 37 and oxygen saturations falling to 86% on 5 L/min oxygen through nasal cannulae). CPAP was recommenced with titration of pressure and FiO₂ as earlier described. A feeding NG-tube was reinserted. A repeat CXR [Figure 1c] showed worsening infiltrates bilaterally, suggestive of ARDS and there was a concomitant rise in CRP levels [Figure 2]. Along with raised CRP levels, interleukin-6 levels were raised at 50.1 pg/mL (0–7), ferritin levels were 302 $\mu\text{g/L}$ and D-dimer

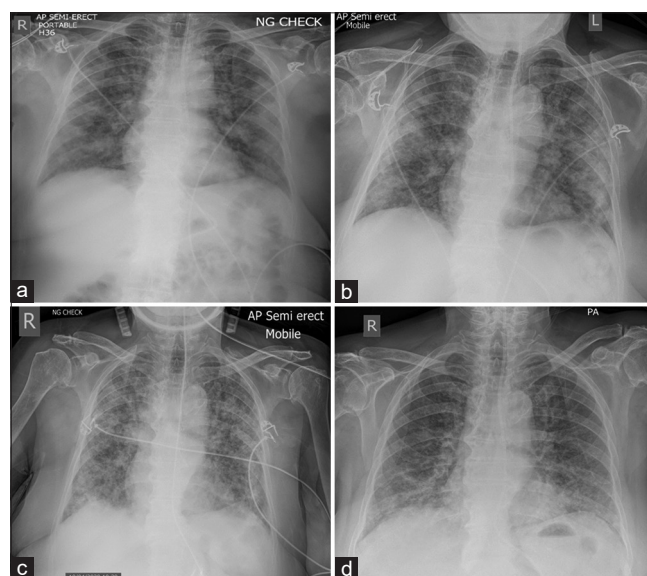


Figure 1: Serial chest X-rays showing the evolution characteristics changes in our patient. (a) Day 4: Showing the early bilateral infiltrates and positioning of the nasogastric tube. (b) Day 10: Worsening of the bilateral infiltrates (c) Day 15: Extensive bilateral infiltrates in keeping with a picture suggestive of ARDS. (d) Day 29: Chest X-ray prior to discharge demonstrating significant improvement in the previously seen infiltrates

4236 ng/mL. Although the clinical picture was in keeping with worsening COVID-19, empirical antibiotic therapy with piperacillin-tazobactam was restarted to cover for hospital-acquired pneumonia. However, multiple sputum and blood cultures did not demonstrate growth of pathogens. The patient slowly improved and was again weaned from CPAP with this being discontinued on day 27 of admission, completing 24 days of CPAP treatment in total. Clinical improvement was reflected in the decline of CRP levels to 11 mg/L from a high of 314 mg/L. Interleukin-6 levels also decreased to 14.2 pg/ml. She was discharged after 30 days of treatment for COVID-19 at which time she no longer required supplementary oxygen and was close to her normal premorbid state. The progression of our patient's clinical observations, CPAP settings, and CRP levels are summarized in Table 1, supporting the "biphasic" nature of our patient's condition.

DISCUSSION

The use of CPAP in hypoxemic COVID-19 patients offers a low-cost, readily available and non-invasive treatment option.^[7,8] It has now become the primary modality of respiratory support in hypoxemic COVID-19 patients in the UK who are not deemed fit for endotracheal intubation.^[10] Despite early apprehension to the use of CPAP, with some national guidance advising against its use, more recent data suggest it could be vital in preventing progression to intubation as well as a ceiling of care in more frail patients. The ease of production and use of CPAP masks makes them suitable for temporary "nightingale" wards and hospitals which have formed an important part of many countries' response to the rising number of cases and the resulting pressure on existing health care resources.^[12] However, evidence suggests that noninvasive ventilatory support, such as CPAP, carries the greatest magnitude of aerosol generation and therefore operators need to wear appropriate personal protective equipment (PPE) whilst attending to these patients.^[13,14] Such PPE can be expensive and countries, including the UK, have encountered difficulties with supply.

As a noninvasive form of ventilatory support administered in conscious patients, CPAP can be provided outside the

intensive care unit setting by adequately trained nursing staff. Continuous monitoring may be helpful; however, the patient-to-nurse ratio required is less as compared to an intubated and mechanically ventilated patient on an intensive care unit. The tolerability of CPAP is variable; in the unrelated condition of obstructive sleep apnea patients use CPAP at night, on a regular basis. Our patient tolerated treatment with CPAP very well and cessation of treatment with CPAP on the grounds of intolerance or futility was never considered. Tolerability may depend on the patient's and clinician's perception of efficacy. There are almost no absolute contraindications to treatment with CPAP and complications other than intolerance are uncommon.

Our case demonstrates a "biphasic" course that has been described in early reports on the natural history of COVID-19. Initial presentation with pyrexia, cough, and systemic symptoms, is thought to be directly related to increasing viral load. This first "phase" may be reflected in the patient's lymphocyte count, with lymphopenia potentially attributable to a high viral load.^[15] This is observed in our patient's lymphocyte count in the 1st week of admission which normalizes early, in keeping with clinical improvement [Figure 3a], likely reflecting a reduction in viral load.^[4] The second "phase" of

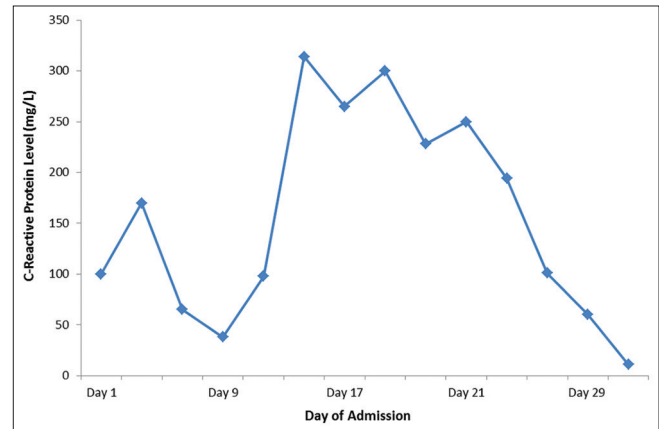


Figure 2: Line graph showing the temporal trend of the patient's C-reactive protein level (mg/L). Initial C-reactive protein levels are raised followed by an initial improvement. There is again an increase to an even higher level, thought to be due to the aberrant host response

Table 1: Some representative measures displaying our patient's clinical condition aligned with specific days of their admission

CPAP status	Day 1	Day 3	Day 4	Day 10	Day 12	Day 15	Day 19	Day 23	Day 29
	No CPAP - 6 L/min O ₂	15 cm H ₂ O - 60% O ₂ 24 h	15 cm H ₂ O - 90% O ₂ 24 h	8 cm H ₂ O - 30% O ₂ 24 h	8 cm H ₂ O - 30% O ₂ 5.5 h	10 cm H ₂ O - 40% O ₂ 24 h	10 cm H ₂ O - 40% O ₂ 24 h	10 cm H ₂ O - 30% 18 h	No CPAP - Room air
Mean SpO ₂ (%)	90.8	91.0	91.7	89.5	88.7	84.7	89.8	91.2	92.0
Mean respiratory rate (breaths per min)	17.2	22.8	22.7	19.0	19.8	23.8	29.2	22.8	18.4
Means NEWS* score	3	3.8	4.5	4.3	4.2	5.8	5.5	4.5	1.1
CRP (mg/L)	100	N/A	170	98	N/A	314	228	101	11

We can visualize the patient's progression in a 'biphasic' pattern with initial improvement by day 10 after the initial deterioration requiring CPAP. This was followed by a second deterioration, which peaked by around day 15–19, before an ultimate recovery prior to discharge. *NEWS – A cumulative score based on the patient's vital observations, widely used in the UK to monitor patient's clinical condition, with more points scored for worse observations.^[11] CPAP: C-reactive protein measurements, NEWS: National Early Warning Score, CRP: C-reactive protein

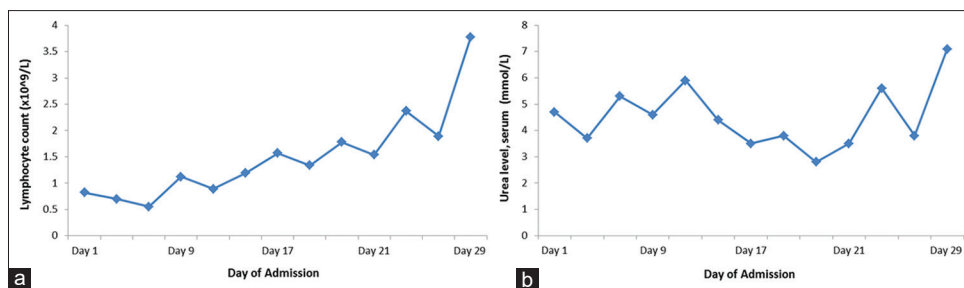


Figure 3: (a) Line graph representing the patient’s lymphocyte count throughout admission. Conveying an initial lymphopenia, thought to be associated with a higher viral load, and eventual normalization. Normal range: $0.8\text{--}3.4 \times 10^9$. (b) Line graph demonstrating the patient’s serum urea concentration throughout admission, which shows a serum level within normal limits throughout admission. Normal range: $3.0\text{--}7.6$ mmol/L

deterioration is thought to be linked to an aberrant host response, dubbed the “cytokine storm,” which leads to the acute inflammatory response within the lung tissue.^[16] Our patient exhibited this with her subsequent clinical deterioration along with a rise in inflammatory markers [Figure 2]. The second deterioration of our patient was more severe than the first; the CPAP and oxygen requirements were higher; the chest X-ray changes were more widespread and CRP levels greater compared to admission. This suggests that the host response is an important contributor to patient mortality. This actuality may be a vital factor as to why we have observed positive, albeit preliminary, data from the RECOVERY trial which demonstrated a significant reduction in mortality for patients receiving Dexamethasone in the specific group of patients requiring supplemental oxygen or ventilatory support, with a more modest effect in those with milder illness.^[17] Selective cytokine inhibitors may also have some benefit in the context of this inflammatory response; there is some data on the use of tocilizumab, a recombinant humanized monoclonal antibody to the IL-6 receptor.^[18]

Our case highlights the necessity for holistic care of the COVID-19 patient requiring ventilatory support. Patients may be more susceptible to nosocomial infection due to bronchial and alveolar inflammation.^[19] Although our patient received empirical antimicrobial therapy to cover possible secondary bacterial infection, the clinical picture and progressive rather than new discrete infiltrates on the chest X-ray led us to feel that the worsening was more likely due to the inflammatory response to COVID-19. By the time the patient was discharged the chest X-ray was improving [Figure 1d]. Adequate hydration and nutrition are vital components of the treatment of COVID-19 patients, with enteral nutrition believed to be central to supporting patients with poor oral intake during prolonged periods of non-invasive respiratory support.^[20] NG feeding is a cheap, reliable, and easy-to-use technique that can support patients who require protracted periods of CPAP. It has the capacity to provide vital nutritional support, especially in the context of limited access to medical expertise, for instance in rural India. NG tube insertion also allows the administration of water into the gastrointestinal tract helping keep the patient euvolemic without recourse to intravenous fluids. In our patient, this is reflected in her

urea measurement throughout admission [Figure 3b]. Adequate fluid balance is essential in COVID-19 patients as they are prone to acute renal failure, which may increase the patient’s risk of thrombosis. Although the exact mechanism is unclear we know that thrombotic events occur in up to 31% of critically ill COVID-19 patients.^[21,22] A NG-tube may also help in decompressing the stomach, a possible complication of CPAP.

CONCLUSION

COVID-19 cases are rising rapidly in countries across the world, including India. Resources to fight this public health emergency are limited, and it is of utmost importance that low-cost, reproducible protocols are generated for hypoxemic patients. Previous articles in *Lung India* have mentioned the possible need for make-shift hospitals and temporary wards.^[23,24] We believe that the interventions that have been used in this case study are suited for large scale management of critically ill patients. The use of CPAP masks and nasogastric tubes are relatively low-cost interventions and do not require extensive training to implement, making them germane treatment options for temporary high-dependency units.

Declaration of patient consent

The authors certify that they have obtained all appropriate patient consent forms. In the form the patient(s) has/have given his/her/their consent for his/her/their images and other clinical information to be reported in the journal. The patients understand that their names and initials will not be published and due efforts will be made to conceal their identity, but anonymity cannot be guaranteed.

Financial support and sponsorship

Nil.

Conflicts of interest

There are no conflicts of interest.

REFERENCES

1. Available from: <https://coronavirus.jhu.edu/data/new-cases->. [Last accessed on 2020 Jul 09].
2. Lancet T. India under COVID-19 lockdown. *Lancet* (London, England)

- 2020;395:1315.
3. Docherty AB, Harrison EM, Green CA, Hardwick HE, Pius R, Norman L, *et al.* Features of 16,749 hospitalised UK patients with COVID-19 using the ISARIC WHO Clinical Characterisation Protocol. medRxiv; 2020.
 4. Chen J, Qi T, Liu L, Ling Y, Qian Z, Li T, *et al.* Clinical progression of patients with COVID-19 in Shanghai, China. *J Infect* 2020;80:e1-6.
 5. Schlobohm RM, Falltrick RT, Quan SF, Katz JA. Lung volumes, mechanics, and oxygenation during spontaneous positive-pressure ventilation: The advantage of CPAP over EPAP. *Anesthesiology* 1981;55:416-22.
 6. Rochweg B, Brochard L, Elliott MW, Hess D, Hill NS, Nava S, *et al.* Official ERS/ATS clinical practice guidelines: Noninvasive ventilation for acute respiratory failure. *Eur Respir J* 2017;50:1602426.
 7. Radovanovic D, Rizzi M, Pini S, Saad M, Chiumello DA, Santus P. Helmet CPAP to treat acute hypoxemic respiratory failure in patients with COVID-19: A management strategy proposal. *J Clin Med* 2020;9:1191.
 8. Nicola M, O'Neill N, Sohrabi C, Khan M, Agha M, Agha R. Evidence based management guideline for the COVID-19 pandemic-review article. *Int J Surg* 2020;77:207-16.
 9. Rockwood K, Song X, MacKnight C, Bergman H, Hogan DB, McDowell I, *et al.* A global clinical measure of fitness and frailty in elderly people. *CMAJ* 2005;173:489-95.
 10. Available from: <https://www.england.nhs.uk/coronavirus/wp-content/uploads/sites/52/2020/03/specialty-guide-NIV-respiratory-support-and-coronavirus-v3.pdf>. [Last accessed on 2020 Jul 03].
 11. Available from: <https://www.rcplondon.ac.uk/projects/outputs/national-early-warning-score-news-2->. [Last accessed on 2020 Jul 11].
 12. Available from: <https://www.england.nhs.uk/2020/03/new-nhs-nightingale-hospital-to-fight-coronavirus/>. [Last accessed on 2020 Jul 08].
 13. Available from: <https://www.england.nhs.uk/coronavirus/wp-content/uploads/sites/52/2020/03/specialty-guide-NIV-respiratory-support-and-coronavirus-v3.pdf>. [Last accessed on 2020 Jul 01].
 14. Whittle JS, Pavlov I, Sacchetti AD, Atwood C, Rosenberg MS. Respiratory support for adult patients with COVID-19. *J Am Coll Emerg Phys Open* 2020;1:95-101.
 15. Azkur AK, Akdis M, Azkur D, Sokolowska M, van de Veen W, Brüggem MC, *et al.* Immune response to SARS-CoV-2 and mechanisms of immunopathological changes in COVID-19. *Allergy* 2020;75:1564-81.
 16. Chen J, Qi T, Liu L, Ling Y, Qian Z, Li T, *et al.* Clinical progression of patients with COVID-19 in Shanghai, China. *J Infect* 2020;80:e1-6.
 17. Huang C, Wang Y, Li X, Ren L, Zhao J, Hu Y, *et al.* Clinical features of patients infected with 2019 novel coronavirus in Wuhan, China. *Lancet* 2020;395:497-506.
 18. Horby P, Lim WS, Emberson J, Mafham M, Bell J, Linsell L, *et al.* Effect of Dexamethasone in Hospitalized Patients with COVID-19: Preliminary Report. medRxiv.
 19. Guaraldi G, Meschiari M, Cozzi-Lepri A, Milic J, Tonelli R, Menozzi M, *et al.* Tocilizumab in patients with severe COVID-19: A retrospective cohort study. *Lancet Rheumatol* 2020;2:e474-e484.
 20. Rawson TM, Moore LSP, Zhu N, Ranganathan N, Skolimowska K, Gilchrist M, *et al.* Bacterial and fungal co-infection in individuals with coronavirus: A rapid review to support COVID-19 antimicrobial prescribing. *Clin Infect Dis* 2020. ciaa530.
 21. Barazzoni R, Bischoff SC, Breda J, Wickramasinghe K, Krznaric Z, Nitzan D, *et al.* ESPEN expert statements and practical guidance for nutritional management of individuals with SARS-CoV-2 infection. *Clin Nutr* 2020;39:1631-8.
 22. Klok FA, Kruip MJHA, van der Meer NJM, Arbous MS, Gommers DAMPJ, Kant KM, *et al.* Incidence of thrombotic complications in critically ill ICU patients with COVID-19. *Thromb Res* 2020;191:145-7.
 23. Helms J, Tacquard C, Severac F, Leonard-Lorant I, Ohana M, Delabranche X, *et al.* High risk of thrombosis in patients with severe SARS-CoV-2 infection: A multicenter prospective cohort study. *Intensive Care Med* 2020;46:1089-98.
 24. Christopher DJ, Isaac BT, Rupali P, Thangakunam B. Health-care preparedness and health-care worker protection in COVID-19 pandemic. *Lung India* 2020;37:238-45.